

Antibiotic Decision Making for Acute Otitis Media (AOM)

Examining the Tympanic Membrane

Figure 2 below from the AAP Clinical Practice Guideline, [The diagnosis and management of acute otitis media](#), illustrates differing degrees of TM bulging:

- A. Normal TM
- B. TM with mild bulging
- C. TM with moderate bulging
- D. TM with severe bulging

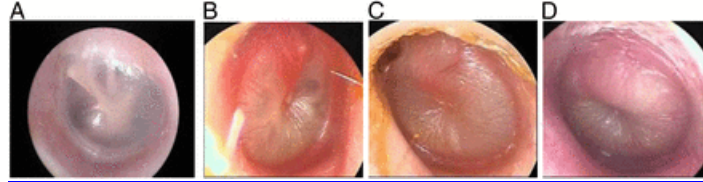


Image provided courtesy of Alejandro Hoberman, MD.

For more visuals on TM bulging, see the NEJM video available titled Otoscopic Signs of Acute Otitis Media on YouTube at: <https://www.youtube.com/watch?v=-6DZJ6Q6N9s>.

